
Contraindications in Anteromedial Osteoarthritis

While it is important to ensure that all the necessary indications are met ¹, it is also important not to apply unnecessary contraindications. Some published lists of supposed contraindications have achieved wide acceptance without having much evidence to support them. We have recently argued with evidence that many of the suggested contraindications are unnecessary ².

The suggested contraindications for UKA are based on Kozinn & Scott's 1989 publication which stated that patients who weigh more than 82 kg, were younger than 60 years, undertook heavy labour, had exposed bone in the PFJ or chondrocalcinosis were not ideal candidates for UKA ³. We wanted to establish whether these potential contraindications should apply to candidates for OUKA. In order to do this, the outcome of patients with these potential contraindications was compared with that of patients without the contraindications in a prospective series of 1000 OUKAs ³. The outcome was assessed using the Oxford Knee Score, American Knee Society Score, Tegner activity score, revision rate and survival. The clinical outcome of patients with each of the potential contraindications was similar to, or better than, those without each contraindication. Overall, 678 UKA (68%) were performed in patients who had at least one potential contraindication and only 322 (32%) in patients deemed to be ideal for UKA. The 10-year survival was 97% (95% CI 93.4 to 100) for those with potential contraindications and 93.6% (95% CI 87.2 to 100) in the 'ideal' patients. This difference was maintained at 15 years as well. The 15-year survival was 94% (95% CI 88 to 100) for those with potential contraindications and 90% (95% CI 78 to 100) in the 'ideal' patients.

Each of these contraindications, and others, are discussed in detail in this chapter.

Patellofemoral arthritis

Almost all authors have included 'patellofemoral arthritis' in the list of contraindications to unicompartmental arthroplasty and it may strike the reader as strange that we have not yet mentioned it in the discussion of AMOA, because, intuitively, associated patellofemoral joint OA must influence the outcome of UKA.

In anteromedial OA, the patellofemoral compartment very commonly exhibits chondromalacia, fibrillation, and cartilage erosions that sometimes expose bone. These lesions are mainly on the medial longitudinal (or 'odd') and medial facets of

the patella and the equivalent surfaces of the femoral trochlea (see Fig. 4.2(g)), but they are also seen astride the median ridge of the patella and in the groove of the trochlea. They are much less common on the lateral facets. Marginal osteophytes are often seen on the preoperative radiographs and even more commonly when the joint is open to inspection.

The presence of any of these lesions has frequently been taken to contraindicate unicompartmental replacement. However, there are some evidence-based arguments for believing that this is unnecessary.

Table 5.1 Patellofemoral state versus postoperative pain (a) at rest and (b) during activity. Each entry in a table gives the number of knees with PFJ state at surgery as defined by the column and the report of pain at last follow-up as defined by the row. Each table is also a graph on which is plotted the linear regression line (shown dashed) that fits the data with minimum squared error. Both lines are nearly horizontal showing that the outcome was independent of the preoperative state.

		Patellofemoral state						Patellofemoral state							
		1	2	3	4	5	Total			1	2	3	4	5	Total
Pain at rest	1	9	21	14	12	3	59	Pain in activity	1	11	22	13	10	3	59
	2	3	4	4	4	0	15		2	2	2	4	6	1	15
	3	2	1	0	2	1	6		3	2	2	3	1	0	8
	4	0	2	0	0	0	2		4	0	2	0	0	0	2
	Total	14	28	18	18	4	82		Total	15	28	20	17	4	84

Patellofemoral state: 1 = good; 2 = moderate; 3 = poor; 4 = grossly disorganized; 5 = previous patellectomy.

Pain: 1 = none; 2 = mild; 3 = moderate; 4 = severe.

We first reached this opinion in 1986⁴ based on a study of 125 bicompartamental Oxford arthroplasties performed for OA (n = 74) or rheumatoid arthritis (n = 51). In these procedures only the tibiofemoral articular surfaces were replaced; the patella and the trochlea were retained. The state of the patella’s articular surface was recorded intra-operatively. At postoperative review (mean follow-up 49 months), no correlation was found between the intraoperative state of the patellofemoral joint and the patients’ postoperative complaints of pain (Table 5.1).

Despite the mixture of diagnoses in this study (and its questionable relevance to unicompartmental replacement), at that time it provided the only scientific evidence on which to base our practice. Accordingly, ever since that publication, we have continued to ignore the state of the patellofemoral joint, whether assessed clinically, radiographically or intraoperatively, when deciding between OUKA and TKA. Subsequently, Carr *et al.*⁵ found no correlation between the perioperative state of the PFJ and the patients’ postoperative complaints of pain at a mean 44 months after surgery in a series of 121 knees treated for anteromedial OA by

OUKA. Despite the degeneration of the PFJ in these patients (and in those of surgeons to whom we have given similar recommendations), patellofemoral problems have rarely been the cause of failure after OUKA ⁶. In all the published series of OUKA with 10-year or longer results that we are aware of, including nearly 10,000 patients, there was not one revised for PFJ problems. The 2004 report from the Swedish Knee Arthroplasty Register gave causes for the 50 revisions from a total of 699 OUKAs, only one of which was for PFJ problems ⁷.

In 28 knees, the state of the PFJ was assessed on radiographs taken 1–2 years after OUKA and was compared with films taken 10+ years later. No significant difference between them was found ⁸. (This study was based on anteroposterior and lateral radiographs of the patellofemoral joint because ‘skyline’ views were not available.)

Beard *et al.* ⁹ have reported on 100 consecutive OUKA cases for anteromedial OA. In all these cases, the location of preoperative pain (anterior, medial, lateral, generalised) was independently determined and the radiological status of the patellofemoral joint was defined using Altman systems ¹⁰. There was no relationship between the presence of the pre-operative anterior knee pain (AKP) and the state of the PFJ. Also pre-operative AKP settled in every case and did not compromise the outcome. We therefore do not consider AKP to be a contraindication.

In this study ⁹, arthritis, however severe, seen on the medial side of the PFJ on the skyline view did not compromise the outcome, so we ignore medial PFJ OA. However, although the numbers were small, there was some evidence to suggest that severe lateral PFJ OA does compromise the outcome. Therefore in the rare cases (less than 1% of patients) when there is severe lateral PFJ OA with bone loss, grooving and subluxation, we would now recommend a TKA.

In a further study of 824 knees in 793 patients, the state of the PFJ peri-operatively was correlated with the clinical outcome ¹¹. There was exposed bone in the trochlea in 15%, on the medial side of the patella in 9%, and on the lateral side in 4%. Exposed bone did not compromise the outcome. Therefore we do not consider exposed bone seen in the PFJ to be a contraindication.

Berend *et al.* ¹² correlated the pre-operative state of the PFJ assessed radiographically with the six year survival in 626 OUKA. 61% of the cases had a normal PFJ and a survival of 94%; 39% had an abnormal PFJ with a 98% survival; and 15% had significant PFJ damage and a 97% survival. There was no statistically significant difference in survival between the groups.

Discussion

Although we cannot offer a full explanation for the (apparent) enigma that the pre-operative state of the patellofemoral joint has so little long-term predictive power, there are considerations that make it less inexplicable than at first sight.

First, similar lesions to those seen radiographically and intraoperatively in anteromedial OA are common in the joints of most middle-aged and elderly people

and, presumably, must be compatible with adequate function. Owre¹³ found flaking and fissuring of some part of the patellar cartilage at necropsy in all but one of 16 subjects aged 60–80 years. Wiles *et al.*¹⁴ recorded that nearly all adult patellofemoral joints showed some pathological changes. The medial border of the medial facet was the most frequent site, and severe degeneration was associated with marginal osteophytes. Outerbridge¹⁵ reported the state of the patellar cartilage during 101 open meniscectomies. He found ‘surface fissuring and fragmentation’ with increasing frequency at each decade in up to 12 of 15 subjects aged 50–69 years. Emery and Meachim¹⁶ gave a detailed description of the topography of surface degeneration at necropsy. They found fibrillation in almost every knee they examined. In young subjects, degeneration was limited to the articular margins and the medial longitudinal facet of the patella, but in middle-aged subjects fibrillation was seen elsewhere on the patella surface. At these sites it became progressively more common and more severe with increasing age, frequently exposing subchondral bone. The cartilage lesions and marginal osteophytes referred to above were all chance findings at necropsy or at arthroscopy performed for reasons not associated with the patellofemoral joint. Therefore the lesions can be assumed to be generally compatible with adequate patellofemoral function. They are likely to be at least as common in the joints of candidates for unicompartamental replacement as they are in the rest of the middle-aged and elderly population, and to have as little significance.

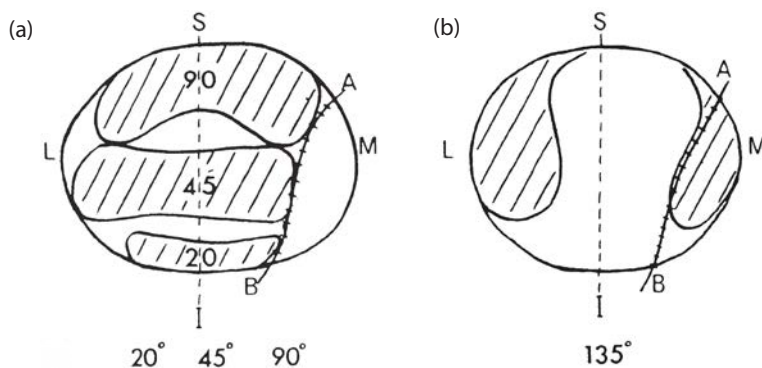


Figure 5.1 Diagrammatic representation of contact areas on the patella in varying degrees of flexion. (Reproduced with permission and copyright © of the British Editorial Society of Bone and Joint Surgery [Goodfellow JW, Hungerford DS, Zindel M. Patellofemoral joint mechanics and pathology. 1. Functional anatomy of the patellofemoral joint. *J Bone Joint Surg [Br]* 1976; **58-B**: 287–90].)

Secondly, lesions on the medial margin of the patella may have no secondary effect on the rest of the knee joint. There are two unusual features of the medial longitudinal, or ‘odd’, facet. It is the *only* part of the patella’s surface that articulates with the medial femoral condyle in full flexion (Fig. 5.1(b))¹⁷. In anteromedial OA, the inferior surface of that condyle is devoid of cartilage, and so it is almost inevitable that the odd facet will be secondarily damaged. However, the odd facet *only* articulates with the femoral condyle, and never with the medial trochlear facet